

THE EFFECT OF LATERAL ELECTRICAL SURFACE STIMULATION (LESS) ON SPINAL DEFORMITY IN IDIOPATHIC SCOLIOSIS*

**Ireneusz M. Kowalski¹, Miguel A. T. Torres²,
Wojciech Kiebzak³, Roman Paśniczek^{4,5}, Józef Szarek⁶**

¹**Department of Rehabilitation, Faculty of Medical Science
University of Warmia and Mazury in Olsztyn, Poland**

²**Centro de Rehabilitacion del Angel in Guadalajara, Jal., Mexico**

³**Department of Fysiotherapy, Faculty of Health Science
University in Kielce, Poland**

⁴**Institute of Precision and Biomedical Engineering, Warsaw Technical
University, Poland**

⁵**Rehabilitation Clinic, Medical University in Warsaw, Poland**

⁶**Faculty of Veterinary Medicine, University of Warmia and Mazury
in Olsztyn, Poland**

Abstract

Clinical studies were carried out in the period of 2003-2008 at the Provincial Children's Rehabilitation Hospital in Ameryka near Olsztyn (Poland). The study involved a group of children and youths exhibiting spinal deformity progression in idiopathic scoliosis (IS) of more than 5° per year according to the Cobb scale. Four hundred and fifty patients between 4 and 15 years of age were divided into three groups ($n = 150$). Group I received 2-hour and group II 9-hour treatment of Lateral Electrical Surface Stimulation (LESS), respectively, whereas group III (control) was treated only with corrective exercises for 30 minutes twice a day. LESS was performed as 24-month treatment with the use of a battery-operated SCOL-2 stimulator manufactured by Elmech, Warsaw, Poland.

The effectiveness of this method was confirmed in the treatment of spinal IS in children and adolescent patients, especially when the initial spinal deformity does not exceed 20° according to the Cobb scale. A short-duration electrostimulation – 2 hours daily – was

prof. nadz. dr hab. med. Ireneusz M. Kowalski, Department of Rehabilitation, University of Warmia and Mazury in Olsztyn, Poland, e-mail: klinika@ameryka.com.pl

*This article has been partly financed by the research fund for 2007-2009.

found to produce results similar to those obtained after overnight, 9-hour electrostimulation. Moreover, the analysis of the Harrington prognostic index F confirms the positive effect of LESS in both groups of patients (2 h and 9 h of LESS).

Key words: electrostimulation, LESS, rehabilitation, idiopathic scoliosis.

WPLYW BOCZNEJ ELEKTRYCZNEJ POWIERZCHNIOWEJ ELEKTROSTYMULACJI (LESS) NA DEFORMACJĘ KRĘGOSŁUPA W SKOLIOZIE IDIOPATYCZNEJ

Abstrakt

Badania kliniczne prowadzono w latach 2003-2008, w Wojewódzkim Szpitalu Rehabilitacyjnym dla Dzieci w Ameryce k. Olsztyna, w grupie dzieci i młodzieży wykazującej progresję skrzywienia w skoliozie idiopatycznej (SI) powyżej 5° wg Cobba w skali rocznej. Badaniami objęto 450 pacjentów, w wieku od 4 do 15 lat, podzielonych na 3 grupy ($n = 150$). W grupie I stosowano 2-godzinną terapię metodą Bocznej Elektrycznej Powierzchniowej Elektrostymulacji (Lateral Electrical Surface Electrostimulation – LESS), w grupie II – 9-godzinną, a w grupie III (kontrolnej) – tylko leczenie za pomocą ćwiczeń korekcyjnych wykonywanych 2 razy po 30 min dziennie. Elektrostymulację typu LESS stosowano, w 24-miesięcznym leczeniu za pomocą bateryjnego stymulatora SCOL-2, wytwarzanego w zakładach elektromechaniki medycznej Elmech w Warszawie.

Efektywność tej metody oceniano podczas leczenia SI kręgosłupa u dzieci i młodzieży, zwłaszcza w przypadkach, gdy początkowe skrzywienie kręgosłupa nie przekraczało 20° wg metody Cobba. Elektrostymulacja LESS skrócona do 2-godzinnej terapii dziennie wywoływała podobnie korzystne rezultaty do osiąganych podczas elektrostymulacji całonocnej – 9-godzinnej. Także wykonana analiza współczynnika prognostycznego F Harringtona potwierdziła pozytywne efekty oddziaływania metody LESS w obydwu grupach pacjentów (I i II).

Słowa kluczowe: elektrostymulacja, LESS, rehabilitacja, skolioza idiopatyczna.

INTRODUCTION

Idiopathic scoliosis (IS) in children and adolescents is an important problem for treatment centres due to its quite high prevalence. It has been estimated that globally this problem, depending on the method and the region, concerns from 0.3 to 15.3% of the population. In Poland, the incidence of this condition ranges from 2 to 14%, while in Western Europe it involves 2 to 3 % of the population. The majority (80-90%) of reported spinal deformities are those of idiopathic scoliosis (IS), i.e. arising from unknown cause (AHN et al. 2002, CHEN 2003, KOWALSKI 2004).

A wide variety of kinesitherapeutical methods applied in spinal lateral deformity (SLD) treatment have an undeniable effect stopping progression of the deformity, although current procedures are influenced by the interpretation of the pathogenesis of this condition (AHN et al. 2002, CHEN 2003, KOWALSKI 2004).

Based on electromyographic studies, a decreased activity at the concave side has been observed in the superficial muscles stabilizing the spine. Excessive activity of the convex side indicates a defensive response so as to maintain the spine in an upright position. This indicates an asymmetric activity of the muscles stabilising the spine (HIRAYAMA et al. 2001, WRIGHT et al. 1992).

However, asymmetric exercises have long been shown to be ineffective because certain spinal muscles, especially the intervertebral muscles, are not amenable to exercises aimed at their selective strengthening or loosening (DURMALA et al. 2003).

In recent years, attention has been paid to the disorders of the nervous-muscular system and their secondary effect on lesions in the spinal osteoarticular-ligament system as one of the potential causes of IS (KOWALSKI 2003, KOWALSKI et al. 2001, 2004). Therefore, LESS was introduced into the conservative treatment of IS.

The aim of this study was to determine the effectiveness of LESS therapy in treating children and youths with IS.

MATERIAL AND METHODS

Clinical studies, part of a research project financed by the State Committee for Scientific Research, were carried out in the years 2003-2008 at the Provincial Children's Rehabilitation Hospital in Ameryka near Olsztyn. The study involved a group of children with the progression of the spinal deformity of more than 5° per year according to the Cobb method. In all the cases examined, scoliotic deformity was located within the thoracic segment of the spine between Th4 and L1. The Cobb deformity angle in the children examined ranged from 10° to 39° . The study involved 450 children and teenagers between 4 and 15 years of age divided into three groups ($n = 150$): group I and group II with 2-hour and 9-hour LESS, respectively, and group III – a control group.

Children in both stimulated (LESS) groups had additional corrective exercises at home, applied twice daily for 30 minutes, while children in group III were only treated with the same corrective exercises.

Electrical stimulation was performed with the use of a battery-operated SCOL-2 stimulator produced by Elmech, Warsaw (KOWALSKI, 2003 KOWALSKI et al., 2004, 2001, 2004). The stimulator's technical parameters were as follows: rectangular approx. 0.1 ms impulses and frequency of 20-55 Hz, duration of the impulse series of 3.5-4.5 s, impulse series intervals of 4-12 s, and the stimulation current amplitude range of 5-75 mA. The impulse waveforms during laboratory trials were recorded on a TEKTRONIX oscilloscope using a state-of-the-art technique for imaging electric signals.

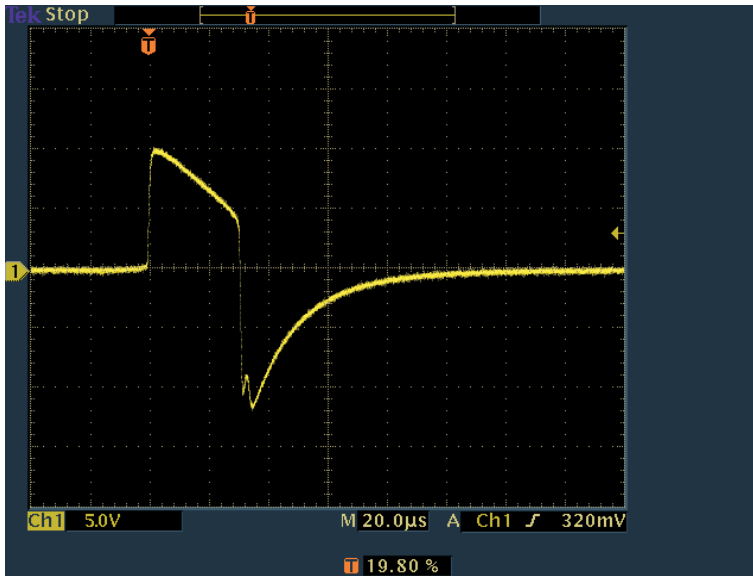


Fig. 1. Plot of minimum impulse amplitude set to 5 of scale

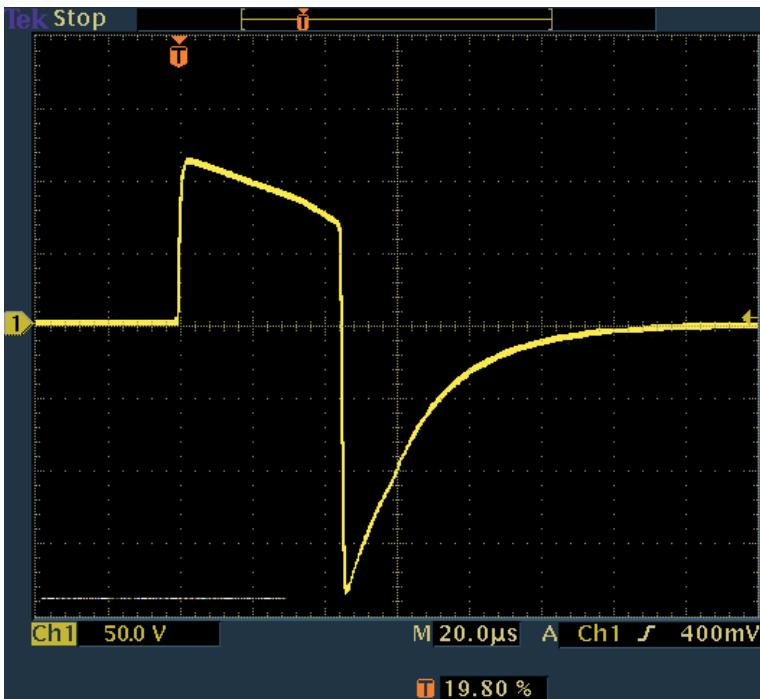


Fig. 2. Plot of maximum impulse amplitude set to 30 of scale

Impulses generated by the stimulator have the form of slightly differentiated rectangles, registered in a stimulator using a substitute resistance of 5.1 k Ω , similar to human tissue resistance (Figures 1, 2).

Electrical stimulation of trunk muscles was performed with superficial disc-shaped electrodes approximately 20 mm in diameter. The conductive rubber electrodes were placed along the scoliotic deformity every 6-12 cm, depending on its length, which is on average 10 cm.

It is recommended that the electrode be located below the blade of the shoulder blade alongside the spinal line at the convex side of the scoliotic deformity. There are three possible locations of the electrodes: medial, intermediate and lateral. Based on preliminary studies, the intermediate location ensures the best conditions of stimulation. In this location, the effect of LESS, both after long-duration (9 h) and short-duration (2 h) electrostimulation, was analysed in all cases.

The effectiveness of the LESS treatment was evaluated from the measurements of the initial spinal deformity angle prior to the treatment and that after 24-month treatment (including corrective exercises in combination with stimulation or only corrective exercises in the control group). The deformity angle was measured in an upright position in an a-p projection according to the Cobb method in three subranges of angle value: 10-19°, 20-29° and 30-39°. The mean value of the deformity angle before treatment and the mean deformity decrease or scoliosis progression after treatment were determined for each experimental group. Moreover, the Harrington prognostic co-efficient F, defined as equal to the Cobb deformity angle divided by the number of vertebrae within the deformity, was determined.

All clinical results were statistically analysed with *t*-Student test.

RESULTS

The clinical results obtained after therapy with LESS (Figure 3) depended on the deformity angle range to which the patients were qualified before treatment. In the 10-19° range, some improvement after treatment was observed: on average 2° decrease in deformity angle size. This value is statistically significant at $p=0.01$. The LESS treatment proved to have a significantly positive effect in 75.5% of all cases of small deformities. In the 20 - 29° range, only a slight (0.3°) improvement in the scoliosis angle was observed after treatment. Stabilisation was observed in almost half of the patients, whereas in the 30-39° range a mean 1.4° scoliosis progression (not statistically significant) was recorded after treatment. Therefore, the therapeutic effect in this group of patients was small.

In the group of scolioses treated with LESS, the best therapeutic effect was obtained in patients with an initial spinal scoliosis angle below 20° according to Cobb method.

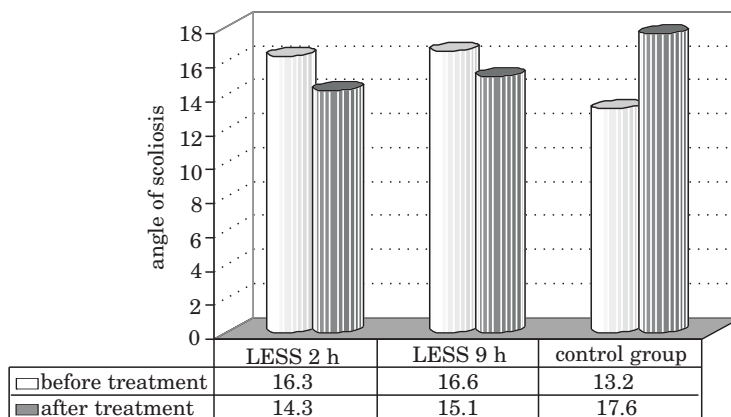


Fig. 3. Mean values of the deformity angle before and after treatment

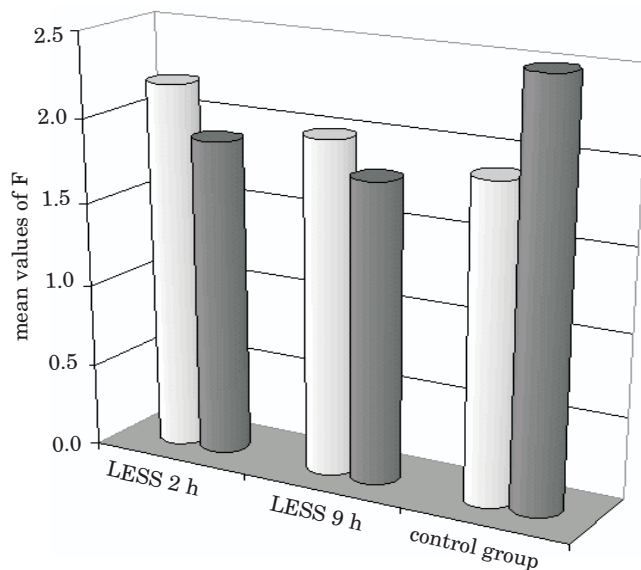


Fig. 4. Mean values of the F co-efficient before and after treatment

Moreover, the analysis of the Harrington prognostic index F confirms the positive effect of LESS in both groups of patients 2 h and 9 h of LESS treatment (Figure 4).

In the control group, scoliosis progression of approximately 4° according to Cobb method (statistically significant at $p=0.01$) was observed despite 24-month rehabilitation.

DISCUSSION

Currently, functional electrostimulation of the nervous-muscular system (FES) generates positive effects. An ever-growing number of applications of electrostimulation as a supportive factor in other treatment methods has been observed. Results of studies carried out at different centres justify the application of LESS in the treatment of IS (KOWALSKI et al. 2004, ANCIAUX et al. 1991, AXELGAARD et al. 1983, BOBECHKO et al. 1979). Electrostimulation of spinal muscles is the only method which can protect asymmetric activity of spinal muscles including intervertebral muscles. Therefore, the non-invasive LESS method will hopefully be used in the treatment of children with IS (KOWALSKI et al. 2004, ANCIAUX et al. 1991, AXELGAARD et al. 1983, BOBECHKO et al. 1979). It can, however, only be used in grade I° scoliosis, where there are no profound morphological lesions and no degenerative changes in concave side muscles (Anciaux et al. 1991, AXELGAARD et al. 1983, BOBECHKO et al. 1979).

BOBECHKO et al. (1979) was first (1974) to introduce electrostimulation for treating IS using superficial electrodes and then electrodes implanted into perispinal muscles. By implanting electrodes he wanted to reach deep layers of segmental muscles. Stimulation was performed in a horizontal position while sleeping, and lasted from 8 to 10 h. In 1983, Axelgaard (AXELGAARD al. 1983) showed that percutaneous electrostimulation with electrodes placed on the patient's back also produced advantageous results compared with those obtained with implanted electrodes. An increase in muscle tension can be obtained by direct stimulation of a muscle or by a reflex arc as well as by excitation causing facilitation of or decrease in inhibiting excitation (WRIGHT et al. 1992).

The results obtained by BOBECHKO et al. (1979) were encouraging enough for many authors to introduce electrostimulation among the methods used in treating spinal lateral scolioses. The main goal of LESS is to replace the non-existing or reinforce the defective bioelectrical activity with adequately formed series of electrical impulses acting directly on the affected nervous-muscular structures. An advantage of electrostimulation is the excitation of afferent nervous fibres through which the spinal cord structures are excited. Thus a substitute excitation model is initiated or a new stereotype of muscle activity control system is created (WRIGHT et al. 1992, BOBECHKO et al. 1979).

Over the last twenty years there have been many reports on the effects of LESS functional electrostimulation on reducing or stopping progression of the disease, or even a decrease in the initial spinal scoliosis. The results concerning the effectiveness of LESS are unequivocal especially as regards the range of the angular deformity for which this type of therapy could be used without causing side effects (KOWALSKI et al. 2004, ANCIAUX et al. 1991, AXELGAARD et al. 1983, BOBECHKO et al. 1979, BUCIŃSKI et al. 2004).

Weiss and Pańniczek were first in Poland to apply electrostimulation (WEISS et al. 1983, PAŚNICZEK et al. 2005). At the Konstancin Rehabilitation Centre (1979-80) they used electrostimulation to excite the perispinal muscles at the convex side of grade II° scoliosis in children between 11 and 14 years of age during scoliosis progression. The stimulations were performed according to an empirically established programme which included 3-month cyclic stimulations lasting 8 to 10 hours carried out during sleep. The results were positive: spinal scoliosis diminished after treatment, which was confirmed by radiological examinations. However, long-term results of the improvement have not been analysed (WEISS et al. 1983, PAŚNICZEK et al. 2005, ZARZYCKI et al. 1991).

In this paper an attempt has been made to prove that the LESS method of treating IS (KOWALSKI 2003, KOWALSKI et al. 2004, 2001, 2004) produces similar or even better results than traditional procedures. The results of the research which has been carried out by KOWALSKI since 1986 (partly presented in this paper) on a large group of children with IS prove that LESS has a good effect on the reduction or stabilisation of scoliosis. Based on these studies, the best treatment can be obtained when the initial scoliosis is less than 20°, measured according to Cobb method. KOWALSKI also found that the inconvenience of overnight therapy could be reduced by proposing a 2-h evening therapy with LESS, which is equally effective as an all-night 8-h stimulation (KOWALSKI 2003, KOWALSKI et al. 2004).

CONCLUSION

1. The analysed LESS method has a good effect on the nervous-muscular system in the therapy of children and youths with IS.
2. LESS has been found to be an effective method in treating IS, especially in cases where the initial spinal scoliosis is less than 20° according to Cobb method.
3. Short-duration electrostimulation (2h daily) produces similarly positive effects to those obtained after all night electrostimulation (9h) and eliminates undesirable symptoms of all night LESS therapy.
4. The analysis of the Harrington prognostic co-efficient F confirms the positive effect of LESS in both groups of patients (2 h and 9 h of LESS).

REFERENCES

- AHN U.M., AHN N., U., NALLAMSHETTY L., BUCHOWSKI J.M., ROSE P.S., MILLER N.H., KOSTUIK J.P., SPONSELLER P.D. 2002. *The etiology of adolescent idiopathic scoliosis*. Am. J. Orthop., 31(7): 387-395.
- CHEN P.Q. 2003. *Management of scoliosis*. J. Formos. Med. Assoc., 102(11): 751-761.

- KOWALSKI I.M. 2004. *The influence of central nervous system on the shaping of human body*. Eurorhab., 14 (3): 132-136 .
- HIRAYAMA J., TAKAHASHI Y., NAKAJIMA Y., TAKAHASHI K., YAMAGATA M., MORIYA H. 2001. *Effects of electrical stimulation of the sciatic nerve on background electromyography and static stretch reflex activity of the trunk muscles in rats: possible implications of neuronal mechanisms in the development of sciatic scoliosis*. Spine, 26(6): 602-609.
- WRIGHT J., HERBERT M.A., VELASQUEZ R., BOBECHKO W.P. 1992. *Morphologic and histochemical characteristics of skeletal muscle after long-duration intramuscular electrical stimulation*. Spine, 17(7): 767-770.
- DURMAŁA J., DOBOSIEWICZ K., KOTWICKI T., JĘDRZEJEK H. 2003. *Effect of asymmetric trunk mobilisation on the Cobb's angle value and rotation in children and youth with idiopathic scolioses*. Ortop. Traumatol. Rehab., 5(1): 80-85.
- KOWALSKI I.M. 2003. *Electrostimulation as the physiotherapy of idiopathic scoliosis*. In: Free papers 2nd World Congress of the International Society of Physical and Rehabilitation Medicine – ISPRM (Ed.) Ring H., Soroker N. Monduzzi Editore S.p.A. – MEDIMOND, Bologna, Italy, 351-354.
- KOWALSKI I.M., SZAREK J., ZARZYCKI D., RYMARCZYK A. 2001. *Experimental scoliosis in the course of unilateral surface electrostimulation of the paravertebral muscles in rabbits: effects according to stimulation period*. Eur. Spine J., 10(6): 490-494.
- KOWALSKI I.M., VAN DAM F., ZARZYCKI D., RYMARCZYK A., SEBASTIANOWICZ P. 2004. *Short - duration electrostimulation in the treatment of idiopathic scoliosis*. Ortop. Traumatol. Rehab., 6(1): 82-89.
- ANCIAX M., LENAERT A., VAN-BENEDEN M.L., BLONDE W., VERCAUTEREN M. 1991. *Transcutaneous electrical stimulation (TCES) for the treatment of adolescent idiopathic scoliosis: preliminary results*. Acta Orthop. Belg., 57(4): 399-405.
- AXELGAARD J., BROWN J.C. 1983. *Lateral electrical surface stimulation for the treatment of progressive idiopathic scoliosis*. Spine., 8(3): 242-260.
- BOBECHKO W.P. HERBERT M.A., FRIEDMAN. H.G. 1979. *Electrospinal instrumentation for scoliosis: current status*. Orthop. Clin. North Am., 10(4): 927-941.
- BUCIŃSKI A., BĄCZEK T., KOWALSKI I.M. 2004. *Clinical data analysis with the use of artificial neural networks (ANN) of treatment evaluation in adolescent idiopathic scoliosis*. Adv. Clin. Exp. Med., 13(4): 623-628.
- WEISS M., PAŚNICZEK R. 1983. *Electrostimulation in conservative treatment of spinal lateral scolioses*. In: *Early diagnosis and prevention of spinal lateral scolioses progression. Scientific session proceedings*. PZWL, Warszawa, 129-132.
- PAŚNICZEK R. 2005. *Functional electrostimulation of limbs*. In: *Paediatric rehabilitation – selected issues*. (Eds.) KOWALSKI I.M., LEWANDOWSKI R., Wyd. 2. Wojewódzki Szpital Rehabilitacyjny dla Dzieci w Ameryce, Olsztyn, 118-133.
- ZARZYCKI D., ZARZYCKA M., NOWAK R., TĘSIOROWSKI M. 1991. *Electrostimulation in the treatment of scolioses*. Chir. Narz. Ruchu Ortop. Pol., 56 (1): 9-12.

